

Serum biochemical and histopathological changes in liver and kidney in lambs after zinc oxide nanoparticles administration

H. Najafzadeh¹, S. M. Ghoreishi², B. Mohammadian³, E. Rahimi⁴, M. R. Afzalzadeh⁵,
M. Kazemivarnamkhasti⁵ and H. Ganjealidarani⁵

1. Department of pharmacology & toxicology, Faculty of veterinary medicine, Shahid Chamran University, Ahvaz, Iran;
2. Department of Large Animal Internal Medicine, Faculty of Veterinary Medicine, Shahid Chamran University, Ahvaz, Iran;
3. Department of Pathology, Faculty of Veterinary Medicine, Shahid Chamran University, Ahvaz, Iran;
4. Department of chemistry, Payame Noor University, Tehran, Iran;
5. Department of Large Animal Internal Medicine, Faculty of veterinary medicine, Shahid Chamran University, Ahvaz, Iran

Corresponding author: H. Najafzadeh, email: najafzadeh@scu.ac.ir

Received: 12-12-2012, **Revised:** 15-02-2013, **Accepted:** 16-02-2013, **Published online:** 25-05-2013

How to cite this article: Najafzadeh H, Ghoreishi SM, Mohammadian B, Rahimi E, Afzalzadeh MR, Kazemivarnamkhasti M and Ganjealidarani H (2013) Serum biochemical and histopathological changes in liver and kidney in lambs after zinc oxide nanoparticles administration, *Vet World* 6(8): 534-537, doi: 10.5455/vetworld.2013.534-537

Abstract

Background: Zinc is an essential co-factor for many enzymatic activities and its deficiency may produce clinical signs of parakeratosis, loss and failure of growth of wool and hair in sheep.

Aim: The present study was designed to evaluate the effect of zinc oxide nano-particles (instead conventional zinc oxide) on serum biochemical factors and histopathological changes in liver and kidney of lambs.

Materials and Methods: One group of lamb (4 lambs each group) received zinc oxide nano-particles suspension daily for 25 day. Whole blood sample and serum were collected at the start and the end of study. Activities of lactate dehydrogenase (LDH), alanine aminotransferase (ALT), aspartate aminotransferase (AST), alkaline phosphatase (ALP), blood urea nitrogen (BUN), and creatinine (CR) were measured in serum of lambs. Sections of liver and kidney were stained with hematoxylin-eosin and examined by light microscopy.

Results: Activity of ALP ($p=0.011$) was significantly decreased and creatinine level ($p=0.002$) was significantly increased by zinc oxide nano-particles. Cell swelling, eosinophilic necrosis of hepatocytes, and multifocal interstitial nephritis was observed during histopathological examination.

Conclusion: Results of study suggest that zinc oxide nano-particles may be toxic for use in sheep in zinc deficiency status.

Key words: hepatotoxicity, lamb, renal toxicity, zinc oxide nano-particles

Introduction

In the recent years the application of nano-technology in human and veterinary medicine has shown a great progress. Also, nanotechnology has revolutionized the commercial application of products in the fields of medicine, engineering, manufacturing, and information and environmental technology [1,2]. Zinc oxide (ZnO) nanoparticles are used for industrial and cosmetic purposes. Zinc is an integral component of a wide range of metalloenzymes and acts as a cofactor for RNA and DNA polymerases. It is of particular importance in rapidly-dividing cells, including those of the epidermis [3,4]. Zinc is also essential for the biosynthesis of fatty acids and participates in both the inflammatory and immune systems. It is also involved in the metabolism of vitamin A [3,4]. Zinc deficiency results in failure of keratinization, which leads to parakeratosis, loss and failure of growth of wool and hair, lesions of coronary bands, retarded testicular development and cessation of spermatogenesis in zinc deficient animals [5]. The lesions of the arteriolar walls

of the dermis have also been reported [5]. However, excessive Zn may reduce the absorption of calcium or phosphorus. Zinc deficiency occurs in cattle, sheep, and goats. The disease in sheep is characterized by loss of wool and development of thick and wrinkled skin. Wool eating also occurs in sheep and may be one of the earliest signs noticed in lambs [6]. However, Zinc causes a high incidence of abortions and stillbirths in the ewes [7]. Zinc toxicity in sheep induces pathological changes in the pancreas, kidney, liver, rumen, abomasum, small intestine, and adrenal gland [8]. The potential hazard of high concentration of manufactured nanoscale zinc powder is still unknown and their toxicological data are rather sparse, although the toxicity of normal zinc and zinc compounds has been much reported [9-12].

The aim of this study was to evaluate the oral toxicity of nanoscale Zn oxide in lambs. Additionally, the effects of these particles on the serum biochemical level and tissues were also investigated.

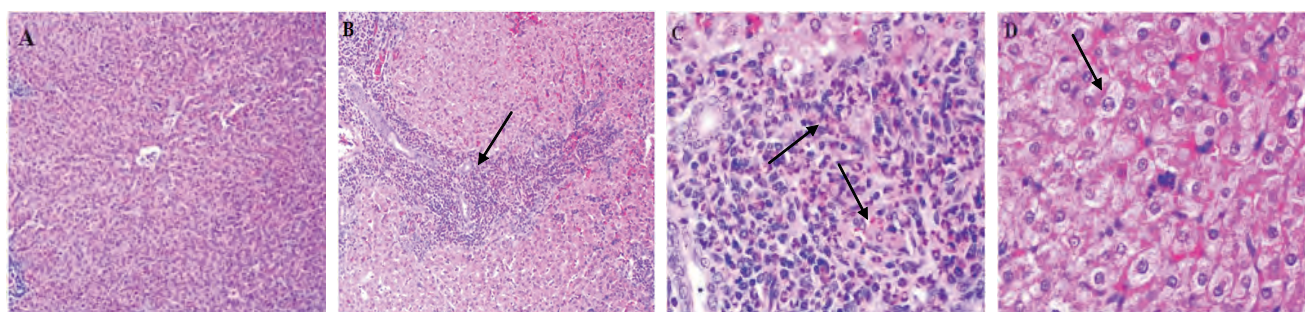
Materials and Methods

Ethical approval: Study was performed according to the 'Guidelines for Animal Experimentation' approved by the Institutional Animal Care.

This article is an open access article licensed under the terms of the Creative Commons Attribution License (<http://creativecommons.org/licenses/by/2.0>) which permits unrestricted use, distribution and reproduction in any medium, provided the work is properly cited.

Table-1. Mean (\pm SE.) of serum factors in lambs under treatment (* represents significant difference between before (day0) and after (day25) treatment with $p < 0.05$).

	Zn ($\mu\text{mol/L}$)	ATL (IU/L)	AST (IU/L)	ALP (IU/L)	LDH (IU/L)	Creatinine (mg/dL)	BUN (mg/dL)
Day0	0.79 \pm 0.09	18.66 \pm 3.71	86.66 \pm 14.24	469.5 \pm 105.40*	1055.5 \pm 209.79	1 \pm 0.04*	15 \pm 1.87
Day25	2.02 \pm 0.78	16 \pm 0.57	91 \pm 29.67	248 \pm 64.16	1008.2 \pm 288.95	1.85 \pm 0.11	19.5 \pm 3.57

**Figure-1.** Liver tissue from lambs control group, lambs exposed to nano zinc at dose of 20mg/kg body weight on 25 days oral administration. (A) Liver in the control group, showing normal structure (10x). (B) Liver in the nano zinc group arrow shows eosinophilic necrosis of hepatocytes (10x). (C) Liver in the nano zinc group arrows show eosinophilic cells (40x). (D) Liver in the nano zinc group arrow shows cell swelling hepatocytes (40x). (H&E).

Sample: The size of the nano particle was determined to be 25nm diameter by transmission electron microscopy. The administered particles were suspended in normal saline and dispersed by vibration for 5 min. The concentration of Zn in the suspension was 200 mg/ml. In order to avoid the aggregation of the particles, a few glass beads were added in the suspension and then stirred on vortex agitator before every use.

Animals: The experiment was began in early July 2011 and finished in September 2011; using eight male lambs (aged 5 - 6 months and weighed 18-20 kg). The animals were purchased from Bervayeh village (Ahvaz, Iran). The animals were housed in clean room and maintained at 32 \pm 35°C, 30-45% relative humidity and 12-h light/dark cycle. The lambs were allowed free access to diet and water. After one week acclimation, the suspension of zinc nanoparticle was oral administration to lambs by dose 20mg/kg body weight. This group received zinc nanoparticles suspension daily for 25 day. Blood was collected from vein before and in the end of study and serum was separated by centrifuge. These samples were stored at -20 C until analysis. The biochemical levels including lactate dehydrogenase (LDH), alanine aminotransferase (ALT), aspartate aminotransferase (AST), alkaline phosphatase (ALP), blood urea nitrogen (BUN), creatinine (CR), were assayed by an automatic biochemical analyzer (Cobas Mira Plus ,Roch Diagnostics, Germany). Level of zinc in serum of lambs was determined at first day and 25 days by Atomic Absorbance Spectrometry (Varian AA-240; Varian Corp, California, USA).

The animals were sacrificed on 25th day. The liver and kidneys were collected, while all tissues were fixed in 10% formalin-buffer for histopathological examination. Then, tissues embedded into paraffin, sectioned for 5 μ m thick, and mounted on the glass microscope slides using standard histopathological techniques. The sections were stained with hematoxylin-eosin and examined by light microscopy.

Statistical analysis: SPSS version 16 (U.S.A.) was used for statistical analysis. Groups' variance was analyzed by one-way Analysis of Variation (ANOVA) and Fisher least significant difference test (LSD) was tested for significant differences between groups. A significant difference was considered to be $p < 0.05$.

Results and Discussion

There was no mortality in nanoparticle group. The amount of serum zinc and the effect of oral administration of zinc nanoparticles on the serum biochemical levels of lambs are shown in Table-1. When zinc level results were evaluated it was observed that, before and after oral exposure to zinc nanoparticles showed an increase zinc level but this sharp elevation was not significant ($p < 0.05$). Table-1 shows The mean concentration of Zn in serum at the end of the experiment was 2.02 μ mol/l in nano zinc group whereas before nano zinc supplement the mean values were around 0.79 μ mol/l.

The results indicated that activity of creatinine was significantly increased compared with the before treatment ($P = 0.002$). The level of the serum ALP was significantly decreased after administration of zinc nanoparticles ($p = 0.011$). The level of other factors did not change significantly (Table-1).

The histopathological pictures of liver are illustrated in Figure-1. At the microscopic level, the liver of lambs nano zinc group presented the reversible histopathological changes as cell swelling (about 50% of lambs was seen) and irreversible histopathological changes as eosinophilic necrosis of hepatocytes (about 50% of lambs was seen). Figure-2 shows histopathological findings of kidney control and nano zinc group. Significant histopathological alteration of kidney tissues nano zinc group was multifocal interstitial nephritis (about 75% of lambs was seen), but remainder of kidney nano zinc group was normal.

Serum level of zinc was increased by oral administration of nano zinc particles in lambs in our study but

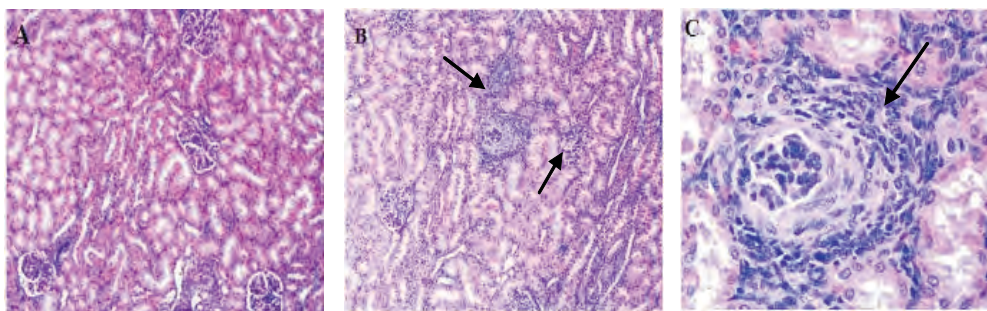


Figure-2. Histopathological findings of kidney of lambs exposed to nano zinc at dose of 20mg/kg body weight on 25days oral administration. (A) Kidney of the control group. There are no significant lesions (10x). (B) Kidney of the nano zinc group arrows show multifocal interstitial nephritis (infiltration of inflammatory cells) (10x). (C) Kidney of the nano zinc group arrow shows glomerular fibrosis (40x). (H&E).

this elevation was not significant. Smith and Embling reported that ZnO administration 240mg/kg/orally for 4 weeks in sheep increased zinc level but this elevation was not significant [13].

The blood biochemical tests are frequently used in diagnosis diseases of liver, kidney. They are also widely used in monitoring the response to the exogenous toxic exposure. In ruminants AST is often tested along with LDH and ALP to evaluate whether the liver is damaged or diseased. When the liver is in dysfunction, the levels of the above enzymes will rise. ALT is considered to be liver specific in cat and dog but there is little hepatic ALT activity in sheep. Clearly shown the value of serum ALT as an indicator of hepatocellular necrosis, especially in dogs and cats, but to a much lesser extent in horses, cattle, swine, sheep, and goats [14]. Therefore, in this study the significantly did not elevate activity of these enzymes but ALP level was significantly decreased and its reason is not clear but may be related to growth of lambs. In addition, the histopathological findings confirm mild liver toxicity by nano zinc (Figure-1). Previous researches reported that liver damage and pancreatic lesions could be induced by excess oral zinc administration [13,15].

The blood BUN and creatinine are good indicators for renal function. If kidney function falls, the BUN and creatinine levels will rise. Thus, the significantly increased creatinine level in the nano zinc group in this study suggested that the renal dysfunction be most likely caused by nano zinc administration. Such result was also obtained from other researches of high zinc salts exposure. Llobet *et al* [10] reported that the concentrations of urea and creatinine in plasma significantly increased after high-dose exposure to zinc acetate dihydrate in drinking water [10]. The histopathological finding demonstrated that the nano zinc oral exposure could cause severe renal damage. Wang *et al* reported that mortality was not observed in mice orally treated with 20 nm or 120 nm ZnO 1 g/kg body weight [16]. Jung *et al* [17] shows that in the mice ALT and AST by serum biochemistry analysis also significantly increased in the ZnO nanoparticles treated group compared with the control group [17]. In the histopathological examination, the liver in mice treated with ZnO nanoparticles showed the edema and degeneration

in the hepatocytes. ZnO particles have dose- and time-dependent cytotoxicity and its mechanism is carried by oxidative stress, lipid peroxidation, cell membrane damage, and oxidative DNA damage [18,19].

Conclusions

Our study suggests that the oral administration of nano zinc may cause toxic effects on the liver and kidney in lambs.

Authors' contribution

All authors contributed equally. All authors read and approved the final manuscript.

Acknowledgments

The authors wish to express their gratitude to the research council of Shahid Chamran University for their financial supports.

Competing interests

The authors declare that they have no competing interests.

References

- Newman, M. D., Stotland, M. and Ellis, J. I. (2009) The safety of nanosized particles in titanium dioxide- and zinc-oxide based sunscreens. *Journal of the American Academy of Dermatology*, 61(4): 685-692.
- Rasmussen, J. W., Martinez, E., Louka, P., Wingett, D. G. (2010) Zinc oxide nanoparticles for selective destruction of tumor cells and potential for drug delivery applications. *Expert Opinion on Drug Delivery*, 7(9): 1063-1077.
- Nishi, Y. (1996) Zinc and growth. *Journal of the American College of Nutrition*, 15(4): 340-344.
- White, C. L., Martin, G. B., Hynd, P. I. and Chapman, R. E. (1994) The effect of zinc deficiency on wool growth and skin and wool follicle histology of male Merino lambs. *British Journal of Nutrition*, 71(3): 425-435.
- Kendall, N. R., McMullen, S., Green, A. and Rodway, R. G. (2000) The effect of a zinc, cobalt and selenium soluble glass bolus on trace element status and semen quality of ram lambs. *Animal Reproductive Sciences*, 62: 277-283.
- Radostits, O. M., Gay, C. C., Blood, D. C. and Hinchcliff, K. W. (2000) *Veterinary medicine*. 9th. edition. Philadelphia: Saunders, W. B. 1510-1513.
- Campbell, J. K. and Mills, C. F. (1979) The toxicity of zinc to pregnant sheep. *Environmental Research*, 20:1-13.
- Allen, J. G., Masters, H. G., Peet, R. L., Mullins, K. R., Lewis, R. D., Skirrow S. Z. and Fry, J. (1983) Zinc toxicity in ruminants. *Journal of Comparative Pathology*, 93(3): 363-377.
- Houston, S., Haggard, J., Williford, J. R., Meserve, L. and

- Shewokis, P. (2001) Adverse effects of large-dose zinc supplementation in an institutionalized older population with pressure ulcers. *Journal of American Geriatric Association*, 49(8): 1130–1131.
10. Llobet, J. M., Domingo, J. L., Colomina, M. T., Mayayo, E. and Corbella, J. (1988) Subchronic oral toxicity of zinc in rats. *Bulletin Environmental Contamination and Toxicology*, 41(1): 36–43.
11. Lock, K. and Janssen, C. R. (2003) Comparative toxicity of zinc salt, zinc powder and zinc oxide to *Eisenia fetida*, *Enchytraeus albidus* and *Folsomia candida*. *Chemosphere*, 53(8): 851–856.
12. Piao, F., Yokoyama, K., Ma, N. and Yamauchi, T. (2003) Subacute toxic effects of zinc on various tissues and organs of rats. *Toxicological Letters*, 145(1): 28–35.
13. Smith, B. L. and Embling, P. P. (1993) Sequential changes in the development of the pancreatic lesion of zinc toxicosis in sheep. *Veterinary Pathology*, 30(3): 242–247.
14. Spano, J. S., August, J. R., Henderson, R. A., Dumas, M. B. and Groth, A. H. (1983) Serum gamma-glutamyl transpeptidase activity in healthy cats and cats with induced hepatic disease. *American Journal of Veterinary Research*, 44(11): 2049–2053.
15. Smith, B. L., Reynolds, G. W. and Embling, P. P. (1979) Effect of method of oral administration of zinc sulphate on acute zinc toxicity in the sheep. *New Zealand Journal of Experimental Agriculture*, 7(2): 107–110.
16. Wang, B., Feng, W., Wang, M., Wang, T., Gu, Y., Zhu, M., Ouyang, H., Shi, J., Zhang, F., Zhao, Y., Chai, Z., Wang, H. and Wang, J. (2008) Acute toxicological impact of nano- and submicro-scaled zinc oxide powder on healthy adult mice. *Journal Nanopart Research*, 10: 263–276.
17. Jung, W. C., Kim, S. and Lee, H. J. (2010) Acute Toxicity of Nano-Scale Zinc Oxide Powder in ICR Mice. *Journal of Biomedical Research*, 11(4): 219–224.
18. Lin, W., Xu, Y., Huang, C., Ma, Y., Shannon, K. B., Chen, D. and Huang, Y. (2009) Toxicity of nano- and micro-sized ZnO particles in human lung epithelial cells. *Journal of Nanoparticles Research*, 11: 25–39.
19. Xia, T., Kovochich, M., Liang, M., Madler, L., Gilbert, B., Shi, H., Yeh, J. I., Zink, J. I. and Nel, A. E. (2008) Comparison of the mechanism of toxicity of zinc oxide and cerium oxide nanoparticles based on dissolution and oxidative stress properties. *American Chemical Society Nanotechnology*, 2(10): 2121–2134.
